

CASE REPORT

Acute hemorrhagic necrotizing pancreatitis in *falciparum* malaria

José Felipe Reoyo-Pascual, Carlos Cartón-Hernández, Xandra Valero-Cerrato, Raquel León-Miranda, Esther García-Plata-Polo, Rosa María Martínez-Castro, Miguel Ángel Álvarez-Rico and Francisco Javier Sánchez-Manuel

Service of General Surgery. Hospital Universitario de Burgos. Burgos, Spain

ABSTRACT

Malaria is a pathology caused by a parasite called *Plasmodium*, characteristic of tropical countries. The most frequent symptomatology includes cerebral malaria, jaundice, convulsive crisis, anemia, hypoglycemia, kidney failure and metabolic acidosis, among others. We are presenting the case of a patient diagnosed with malaria who suffered from acute hemorrhagic necrotizing pancreatitis and evolved poorly, as an example of this combination of symptoms, rarely found in our country.

Key words: Acute pancreatitis. Malaria. *Falciparum*.

INTRODUCTION

Plasmodium falciparum malaria is uncommon in our country. It displays typical symptomatology based on high fever, kidney failure, hematological disturbance, etc. Pancreas affection in the clinical profile of *falciparum* malaria is an unusual combination, seldom found in Europe, which is the reason why we are presenting a case which may suggest its appearance.

CASE REPORT

We are presenting the case of a 62-year-old male, a permanent resident of Angola, with a record of hypertension and hyperuricemia, who is admitted to our hospital with symptoms of fever and constitutional syndrome, which has been developing for one week. When the patient is examined, mucocutaneous jaundice is discovered, without any other pathology. During the analysis, leucocytosis is not observed, demonstrating a total of 6.7 mg/dl of

bilirubin, 1.99 mg/dl of creatinine, 25 UI/l of amylase, 165 mg/dl procalcitonin. In the ultrasonography acalculous gallbladder disease with thin walls can be observed, without any other important discoveries. As he is diagnosed with sepsis accompanied by hematologic, hemodynamic and hepatic kidney failure, the patient is admitted to the Intensive Care Unit. Because it is suspected that he has malaria, a smear is carried out in this unit. As a result, some forms are objectified, which are compatible with *Plasmodium falciparum* (Fig. 1), with an index of > 21% parasitemia. Almost two weeks after the patient's admission to the Intensive Care Unit, he evolves poorly. For this reason, an upper digestive endoscopy is requested, in which one can observe a segmental area of the second part of the edematous duodenum, possibly related

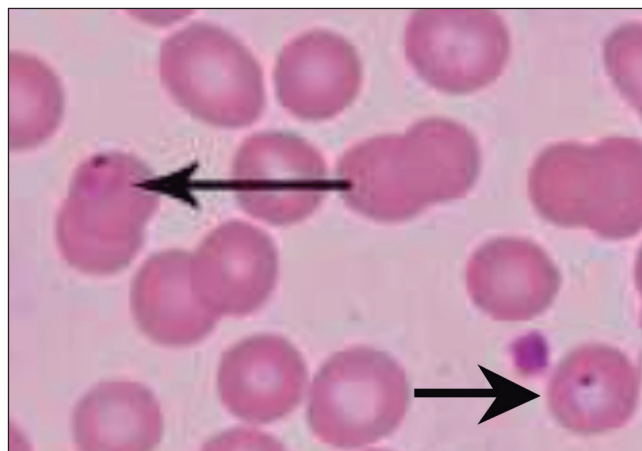

Fig. 1. Smear in which red blood cells parasitized by *P. falciparum* trophozoites are observed.

Received: 14-03-2015
Accepted: 15-04-2015

Correspondence: José Felipe Reoyo Pascual. Department of General Surgery. Hospital Universitario de Burgos. Avda. Islas Baleares, s/n. 09006 Burgos, Spain
e-mail: josefelipe82@hotmail.com

Reoyo-Pascual JF, Cartón-Hernández C, Valero-Cerrato X, León-Miranda R, García-Plata-Polo E, Martínez-Castro RM, Álvarez-Rico MA, Sánchez-Manuel FJ. Acute hemorrhagic necrotizing pancreatitis in *falciparum* malaria. *Rev Esp Enferm Dig* 2016;108:285-287.

to the adjacent inflammatory process or the beginning of ischemia. With these findings and following clinical and analytical deterioration (intense leucocytosis, an increase in acute phase reactants, a discrete increase in amylase) confirming a clinical case of acute abdomen, abdominal CT is carried out, in which a suggestive image of a periduodenal inflammatory process can be observed, as well as hemoretroperitoneum data (Figs. 2 and 3). In the light of this data, and in the presence of the patient's unstable clinical condition, emergency surgery is required, in which duodenal pathology is not detected, revealing necrotizing hemorrhagic peripancreatic sphacelus, retroperitoneal hematoma, as well as globulose pancreas of hardened consistency accompanied by probable areas

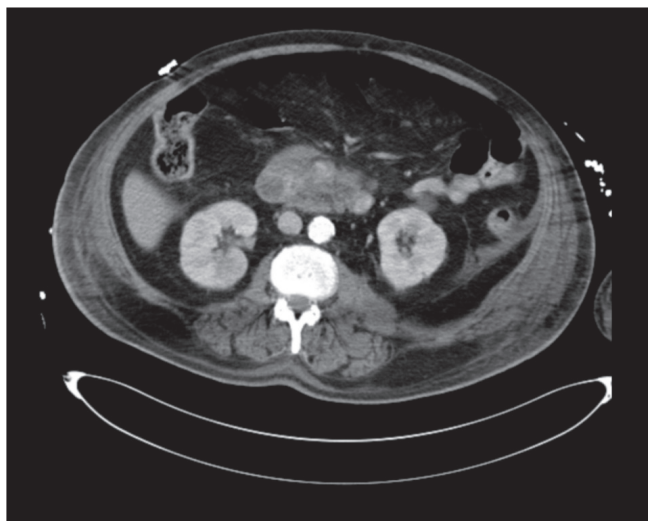


Fig. 2. CT image in which part of an inflammatory periduodenum process is observed.

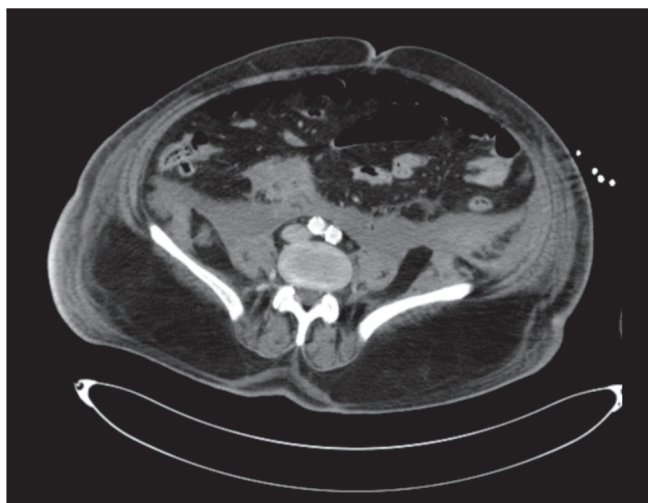


Fig. 3. CT image in which preoperative hemoretroperitoneum is observed.

of steatonecrosis; proceeding to abdominal fluid drainage and admitting the patient to the Intensive Care Unit for observation. Discarding common causes of pancreatitis, such as lithiasis or toxin consumption, which are not found in this patient, and once medical literature is revised, a relation to malaria is suggested. Twenty-four hours after surgery is performed, the patient dies. Consequently, it is not possible to perform a necropsy.

DISCUSSION

P. falciparum malaria is an extremely serious pathology, which involves a great variety of symptoms. The most important are coma, acidosis, anemia, DIC, shock and kidney failure, among others (1). Abdominal pain found in patients affected by malaria can generally be due to the following causes: Acalculous cholecystitis (2), splenic rupture (3), splenic infarction (4), splenic torsion (5), etc. The appearance of acute pancreatitis in patients suffering from malaria was first defined by Egdagl in 1907 (6), in the case of a series of 105 patients. In Asian and African countries, cases of pancreatitis in patients with malaria have been observed. Likewise, in 2007, Seshadri et al. (7) register and report a case of acute pancreatitis, revealing subdural hematoma in a patient suffering from *falciparum* malaria. Other authors such as Sharma et al., in 2012, register a case of acute pancreatitis in a patient with *vivax* malaria (8).

Referring to the physiopathological mechanism, authors such as Desai et al. (9) include pancreas ischemia caused by microvascular occlusion, possibly contributing to the presence of hemolytic anemia, which is characteristic of this pathology. For this reason, pancreatic vascular occlusion with the presence of parasitized erythrocytes caused by plasmodium has been discovered in several autopsies (10). In our case, the diagnosis of pancreatitis was intraoperative, in which it was not possible to confirm the findings with the necropsy; also, discarding other, more frequent causes such as alcohol consumption, cholelithiasis, dyslipidemia, hypercalcemia, toxins, etc. (11). According to what has been stated by authors such as Thapa et al. (12), in the clinical case of acute abdomen in patients suffering from plasmodium *falciparum*, the presence of acute pancreatitis is to be discarded. What we are especially concerned with in our case is not only the unusual relation between malaria and pancreatitis, but also the epidemiological anomaly which supposes the presence of malaria in our surroundings.

In conclusion, acute necrotizing hemorrhagic pancreatitis is a serious disease which must be considered in the case of acute abdomen symptoms found in patients suffering from malaria, after having discarded other, more frequent causes. Early diagnosis and providing early treatment will improve the survival odds of the patient.

REFERENCES

1. Singh J, Dinkar A, Atam V, et al. An uncommon presentation of severe *Falciparum* Malaria: Acute pancreatitis. *Int Res J Medical Sci* 2014;2:26-8.
2. Anthoine-Milhomme MC, Chappuy H, Chéron G. Acute acalculous cholecystitis in a child returning from the Ivory Coast. *Pediatr Emerg Care* 2007;23:242-3, DOI: 10.1097/PEC.0b013e31803f5ab8
3. Jiménez BC, Navarro M, Huerga H, et al. Spontaneous splenic rupture due to *Plasmodium vivax* in a traveler: Case report and review. *J Travel Med.* 2007;14:188-91. DOI: 10.1111/j.1708-8305.2007.00112.x
4. Kim A, Park YK, Lee JS, et al. A case of symptomatic splenic infarction in vivax malaria. *Korean J Parasitol* 2007;45:55-8. DOI: 10.3347/kjp.2007.45.1.55
5. Cross AB. Diagnostic clue to acute splenic torsion in the tropics. *Br Med J.* 1974;3:564-6. DOI: 10.1136/bmj.3.5930.564
6. Egdagl A. A review of 105 reported cases of acute pancreatitis, with special reference to a etiology with report of two cases. *Johns Hopkins Med J* 1907;18:130-2.
7. Seshadri P, Vimal A, Viggeswarpu S, et al. Acute pancreatitis and subdural haematoma in a patient with severe *falciparum* malaria: Case report and review of literature. *Malar J* 2008;7:97. DOI: 10.1186/1475-2875-7-97
8. Sharma V, Sharma A, Aggarwal A, et al. Acute pancreatitis in a patient with vivax malaria. *Journal of the Pancreas* 2012;13:215-6.
9. Desai DC, Gupta T, Sirsat RA, et al. Malarial pancreatitis: Report of two cases and review of the literature. *Am J Gastroenterol* 2001;96:930-2. DOI: 10.1111/j.1572-0241.2001.03658.x
10. Sarma PS, Kumar RS. Abdominal pain in a patient with *falciparum* malaria. *Postgrad Med J* 1998;74:425-7. DOI: 10.1136/pgmj.74.873.425
11. Ghosh S, Kumar S, Sharma A. Unusual presentation of acute pancreatitis in *falciparum* malaria. *Trop Parasitol* 2014;4:56-57. DOI: 10.4103/2229-5070.129188
12. Thapa R, Mallick D, Biswas B. Childhood *Plasmodium falciparum* malaria complicated by acute pancreatitis. *Trop Doct* 2010;40:184-5. DOI: 10.1258/td.2010.090420